

# Inhibition of Corneal Neovascularization by Topically Administered Propranolol in a Rabbit Model

Ali Kasiri<sup>1\*</sup>, Gholam-Reza Hoshmand<sup>2</sup>, Hesam Hedayati<sup>1</sup>,  
Seyed Ahmad Rasoulinejad<sup>1</sup>, Mohammad Montazeri<sup>2</sup>, Niusha Kasiri<sup>2</sup>

<sup>1</sup>Department of Ophthalmology, Ahvaz Jundishapur University of Medical Sciences, Ahvaz, Iran, <sup>2</sup>Faculty of Medicine, Ahvaz Jundishapur University of Medical Sciences, Ahvaz, Iran

## Abstract

**Objective:** To evaluate the effects of topical propranolol for treatment of the corneal neovascularization (CNV) in a rabbit model of corneal injury. **Methods:** The CNV model was induced by 3 sutures of the cornea in 20 rabbits (20 corneas). 2 weeks after CNV, all sutures were removed then rabbits were divided randomly into two groups: Group 1 received topical propranolol 10 mg/mL and Group 2 received only topical normal saline drops as control group, in the right eyes three times a day for 2 weeks. Photographs of (CNV) were obtained before drug administration and at 1 and 2 weeks after therapy. The images were analyzed using NIH Image J1.49c software. **Results:** The mean percentage of CNV area estimated as 100% before treatment. At the 1 week after treatment, the mean percentage of NV area in propranolol and saline group were  $78.01 \pm 4.16$  and  $93.33 \pm 4.57$ , respectively. Moreover, at the 2 weeks after treatment were  $65.72 \pm 4.15$  and  $84.96 \pm 5.21$ , respectively. After 1 and 2 weeks treatment, the NV area in propranolol group was regressed more than saline group significantly ( $P < 0.0001$ ). **Conclusion:** Topical administration of propranolol reduces CNV in the short-term, but the efficacy of long-term treatment needs more investigations.

**Key words:** Corneal neovascularization, propranolol, topical

## INTRODUCTION

Corneal neovascularization (CNV) is a common consequence of various inflammatory, infectious, and traumatic corneal disorders.<sup>[1]</sup> Neovascularization (NV) induces tissue scarring, lipid deposition, stromal hemorrhage, and corneal edema, all of which severely affect visual acuity.<sup>[2]</sup> In addition, vascularity reduces the immune privilege of the cornea and the likelihood of graft survival in patients who subsequently elect to undergo penetrating keratoplasty.<sup>[3]</sup>

Angiogenesis is mediated by several different factors, including vascular endothelial growth factor (VEGF) and platelet-derived growth factor. VEGF is a homodimeric glycoprotein, heparin-binding growth factor specific to vascular endothelial cells commonly considered the most prominent angiogenic factor. Within the VEGF family, VEGF-A is considered to be the major factor involved in hemangiogenesis and has received the most attention as the mediator of pathologic NV. VEGF and its tyrosine kinase

receptors, VEGF receptor 1 (VEGF1), and VEGFR2, promote many aspects of the angiogenic process.<sup>[4-9]</sup>

Propranolol is a nonselective beta-adrenergic receptor blocker drug. Several studies have reported beta-adrenergic system is one of the major stimulating factors that increase VEGF production. Hence, beta-blockers can reduce VEGF production and subsequently regression of NV.<sup>[10,11]</sup> Propranolol has no effect on the normal level of VEGF that its mechanism remained largely unknown.<sup>[11]</sup> Recent studies have shown propranolol can reduce VEGF production in oxygen-induced retinopathy.<sup>[11-13]</sup> Currently, there is no evidence of propranolol effect on CNV except only one study in 2014 that reported a non-significant effect.<sup>[10]</sup>

### Address for correspondence:

Ali Kasiri, Department of Ophthalmology, Ahvaz Jundishapur University of Medical Sciences, Ahvaz, Iran.  
E-mail: alikasiri343@gmail.com

**Received:** 12-05-2017

**Revised:** 23-05-2017

**Accepted:** 28-05-2017

Therefore, the present study was aimed to investigate the anti-angiogenic effects of topical administration propranolol in experimentally-induced CNV in a rabbit model.

## MATERIALS AND METHODS

In this study, 20 wild brown male rabbits, weighing 1500-1900 g, were used. The protocol for this experimental study was approved by the Institutional Animal Care and Use Committee of Ahvaz Jundishapur University of Medical Sciences, Ahvaz, Iran. Animal maintenance and all *in vivo* experiments were performed in accordance with the institutional guidelines and the Association for Research in Vision and Ophthalmology Statement.

The animals were anesthetized by IM injections of tiletamine (2.5 mg/kg body weight), zolazepam (2.5 mg/kg), and xylazine (3.45 mg/kg) if needed. After the application of topical tetracaine, three 7-0 silk sutures were placed radially, at mid-stromal depth, at the 10, 12, and 2 O'clock positions on the corneas of the right eyes, avoiding corneal perforation. Topical ciprofloxacin was instilled twice a day to minimize the risk of infection after surgery. Corneal sutures were removed 2 weeks after suture placement. After suture removal, the 20 rabbits were divided into two groups, with 10 rabbits in each group. In Groups 1 and 2, the right eyes received topical applications of propranolol (10 mg/mL) and saline, respectively. The solutions were administered three times a day for 2 weeks, starting immediately after suture removal. The concentrations of topical Propranolol were chosen from previous studies.<sup>[10,12]</sup>

All treated and control eyes were photographed using a charge-coupled device camera attached to a slit-lamp biomicroscope at  $\times 40$  magnification. Photographs were obtained before drug administration and at 1 and 2 weeks after therapy.

The images were analyzed using NIH image J1.49 software. The resolution of each image was  $640 \times 480$  pixels. All images were converted to tagged information file format files. The quantification of NV throughout the entire cornea was performed in a blinded fashion to minimize sampling bias. The area of corneal vasculature was outlined with the computer mouse and calculated using the Image J software. To control for individual variation in the area of NV induced by the suture, the area before anti-neovascular treatment was set at 100%, and post-treatment area values were presented as the percentage of the remaining NV. This approach for measurement is consistent with the previously described method.<sup>[14-21]</sup>

Statistical analyses were performed using SPSS version 21.0 for Windows. The Mann-Whitney *U*-test was used for comparisons between administrations of two drugs. Differences were considered statistically significant when *P* values were  $< 0.05$ .

## RESULTS

Biomicroscopic examination of the rabbits' eyes at 1 and 2 weeks after the initiation of treatment revealed that CNV in eyes that received propranolol had regressed more than those received saline [Figure 1].

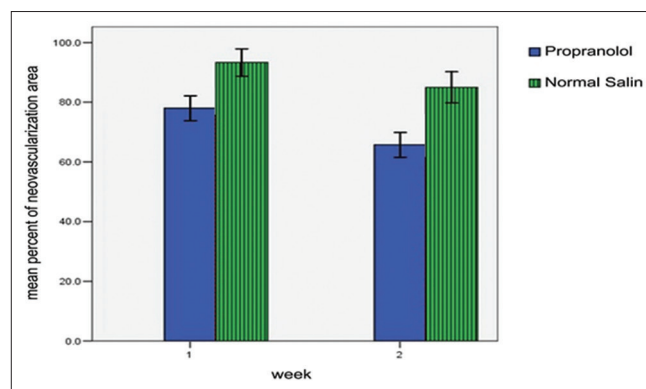
The mean percentage of CNV area estimated as 100% before treatment. At the 1 week after treatment, the mean percentage of NV area in propranolol and saline group were  $78.01 \pm 4.16$  and  $93.33 \pm 4.57$ , respectively. In addition, at the 2 weeks after treatment were  $65.72 \pm 4.15$  and  $84.96 \pm 5.21$ , respectively [Table 1].

After 1 week treatment, the NV area in propranolol group was regressed more than saline group significantly ( $P < 0.0001$ ).

After 2 weeks treatment, the NV area in propranolol group was regressed more than saline group significantly ( $P < 0.0001$ ) [Figure 2].

Figure 3 showed the changes of CNV area in 2 weeks treatment.

The mean percentage of changes of CNV area in propranolol and saline groups were  $34.28 \pm 4.15$  and  $15.04 \pm 5.21$ , respectively [Table 2].



**Figure 1:** Comparison the mean  $\pm$  standard deviation between two groups after 1 and 2 weeks

**Table 1:** Comparison between two groups

Group	After 1 week	After 2 weeks
Propranolol	$78.01 \pm 4.16$	$65.72 \pm 4.15$
Normal saline	$93.33 \pm 4.57$	$84.96 \pm 5.21$

**Table 2:** Comparison between two groups

Group	Mean changes
Propranolol	$34.28 \pm 4.15$
Normal saline	$15.04 \pm 5.21$

The mean percentage of regression of CNV area in propranolol group was different to saline group significantly ( $P < 0.0001$ ).

## DISCUSSION

The treatment of CNV can be challenging and problematic.<sup>[4-8]</sup> Various anti-angiogenic therapy strategies have been used to interfere with the VEGF system. At present, the clinical focus in the treatment of CNV involves the use of antibodies to VEGF.<sup>[9]</sup>

Hashemian *et al.* in 2011 and Öner *et al.* in 2012 have reported a non-significant difference statistically between topical and subconjunctival bevacizumab for CNV in an experimental rat model but both of them were effective.<sup>[15,16]</sup> In our study, topical propranolol has been evaluated and it was effective. Kim *et al.* in 2013 have shown topically administered bevacizumab had longer standing anti-angiogenic effect than subconjunctivally injected bevacizumab in rat CNV. They reported observations of epitheliopathy and corneal thinning

after topical bevacizumab. These adverse effects generally appeared during the 2<sup>nd</sup> month of treatment. On the contrary, in the current study, no instance of epitheliopathy or corneal thinning by topical propranolol was observed. This may be because the study lasted for only 2 weeks, which may be too short a period to allow for the development of epitheliopathy.<sup>[17]</sup>

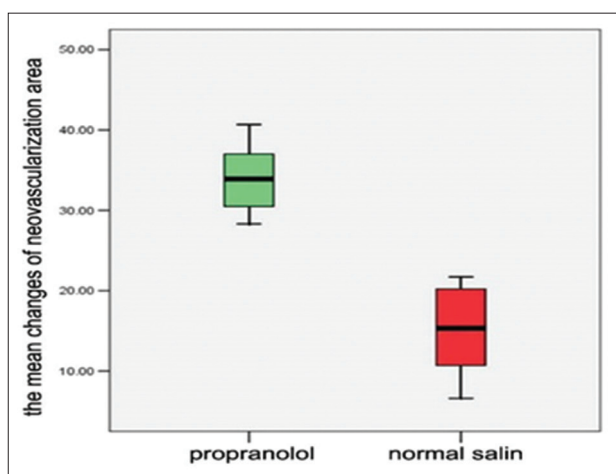
Simavli *et al.* in 2014 have shown topical propranolol has no significant inhibitory effect on CNV statistically.<sup>[10]</sup> While our study shows topical propranolol can inhibit CNV statistically.

Padrini *et al.* in 2014 studied pharmacokinetics and local safety profile of propranolol eye drops in rabbits and reported retinal concentration of propranolol is similar in topically and orally administration.<sup>[22]</sup>

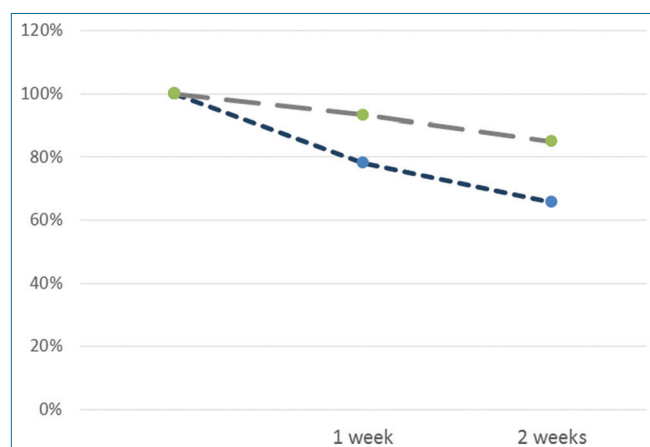
Ristori *et al.* in 2011 studied the role of the adrenergic system in a mouse model of oxygen-induced retinopathy and antiangiogenic effects of beta-adrenoreceptor blockade. They reported beta-receptor blockade is protective against retinal angiogenesis by reducing VEGF but no effect on normal level of VEGF.<sup>[11]</sup>

The results of our experiments demonstrated that regression of CNV area in topical propranolol group was different to saline group significantly, 2.28-fold after 2 weeks.

Several studies have shown that propranolol can reduce VEGF and VEGFR1 and VEGFR2 production and also shown inhibition by propranolol of VEGF-induced tyrosine phosphorylation of VEGFR2 lead to inhibition of downstream signaling such as the activation of the extracellular signal-regulated kinase-1/2 and the secretion of the extracellular matrix degrading enzyme matrix metalloproteinase-2. Taken together, these results demonstrate that propranolol interferes with several essential steps of NV and opens up novel therapeutic opportunities for the use of  $\beta$ -blockers in the treatment of angiogenesis-dependent human diseases. However, its mechanism of action is as yet unknown totally.



**Figure 2:** Comparison the mean  $\pm$  standard deviation between two groups after 2 weeks



**Figure 3:** Comparison the regression of corneal neovascularization between two groups

## CONCLUSION

Our findings strengthen the hypothesis that  $\beta$ -AR blockade can efficiently counteract NV and show topical propranolol can regress CNV in short term period and suggest propranolol as an alternative drug to bevacizumab because it is available and cost-benefit.

Our study suggests that topical eye application of propranolol can represent an alternative delivery route to systemic administration thus avoiding the risk of associated complications and side effects that could make this drug unsafe in long-term treatment.

However, the evaluation of multiple doses of topical propranolol and the efficacy and side effects of long-term treatment for CNV needs more investigations.

The limitations of our study include the short follow-up period and the lack of information about the biocompatibility of topical propranolol. Further, trials with longer periods of follow-up will be necessary. Further, studies of the optimal dosage, treatment interval, and duration are also recommended.

## REFERENCES

1. DelMonte DW, Kim T. Anatomy and physiology of the cornea. *J Cataract Refract Surg* 2011;37:588-98.
2. Chang JH, Gabison EE, Kato T, Azar DT. Corneal neovascularization. *Curr Opin Ophthalmol* 2001;12:242-9.
3. Lee P, Wang CC, Adamis AP. Ocular neovascularization: An epidemiologic review. *Surv Ophthalmol* 1998;43:245-69.
4. Pérez-Santonja JJ, Campos-Mollo E, Lledó-Riquelme M, Javaloy J, Alió JL. Inhibition of corneal neovascularization by topical bevacizumab (Anti-VEGF) and sunitinib (Anti-VEGF and Anti-PDGF) in an animal model. *Am J Ophthalmol* 2010;150:519-28.
5. Pérez-Santonja JJ, Campos-Mollo E, Lledó-Riquelme M, Fernández-Sánchez L, Cuenca-Navarro N. Vascular morphological and microdensity changes of corneal neovascularization induced by topical bevacizumab and sunitinib in an animal model. *Arch Soc Esp Oftalmol* 2013;88:473-81.
6. Tunik S, Nergiz Y, Keklikci U, Akkus M. The subconjunctival use of cetuximab and bevacizumab in inhibition of corneal angiogenesis. *Graefes Arch Clin Exp Ophthalmol* 2012;250:1161-7.
7. Stevenson W, Cheng SF, Dastjerdi MH, Ferrari G, Dana R. Corneal neovascularization and the utility of topical VEGF inhibition: Ranibizumab (Lucentis) versus bevacizumab (Avastin). *Ocul Surf* 2012;10:67-83.
8. Akar EE, Oner V, Küçükerdönmez C, Aydın Akova Y. Comparison of subconjunctivally injected bevacizumab, ranibizumab, and pegaptanib for inhibition of corneal neovascularization in a rat model. *Int J Ophthalmol* 2013;6:136-40.
9. Robinson CJ, Stringer SE. The splice variants of vascular endothelial growth factor (VEGF) and their receptors. *J Cell Sci* 2001;114:853-65.
10. Simavli H, Erdurmus M, Terzi EH, Bucak YY, Önder HI, Kükner AS. The effect of  $\beta$  receptor blockade through propranolol on corneal neovascularization. *J Ocul Pharmacol Ther* 2014;30:650-6.
11. Ristori C, Filippi L, Dal Monte M, Martini D, Cammalleri M, Fortunato P, *et al.* Role of the adrenergic system in a mouse model of oxygen-induced retinopathy: Antiangiogenic effects of beta-adrenoreceptor blockade. *Invest Ophthalmol Vis Sci* 2011;52:155-70.
12. Dal Monte M, Casini G, la Marca G, Isacchi B, Filippi L, Bagnoli P. Eye drop propranolol administration promotes the recovery of oxygen-induced retinopathy in mice. *Exp Eye Res* 2013;111:27-35.
13. Simó R, Carrasco E, García-Ramírez M, Hernández C. Angiogenic and antiangiogenic factors in proliferative diabetic retinopathy. *Curr Diabetes Rev* 2006;2:71-98.
14. Türkcü FM, Cinar Y, Türkcü G, Sahin A, Cingü AK, Yüksel H, *et al.* Topical and subconjunctival ranibizumab (lucentis) for corneal neovascularization in experimental rat model. *Cutan Ocul Toxicol* 2014;33:138-44.
15. Öner V, Küçükerdönmez C, Akova YA, Çolak A, Karalezli A. Topical and subconjunctival bevacizumab for corneal neovascularization in an experimental rat model. *Ophthalmic Res* 2012;48:118-23.
16. Hashemian MN, Z-Mehrjardi H, Moghimi S, Tahvildari M, Mojazi-Amiri H. Prevention of corneal neovascularization: Comparison of different doses of subconjunctival bevacizumab with its topical form in experimental rats. *Ophthalmic Res* 2011;46:50-4.
17. Kim J, Kim D, Kim ES, Kim MJ, Tchah H. Topically administered bevacizumab had longer standing antiangiogenic effect than subconjunctivally injected bevacizumab in rat corneal neovascularization. *Int J Ophthalmol* 2013;6:588-91.
18. Ko BY, Kim YS, Baek SG, Lee GW, Kim JM, Jean WS, *et al.* Inhibition of corneal neovascularization by subconjunctival and topical bevacizumab and sunitinib in a rabbit model. *Cornea* 2013;32:689-95.
19. Hosseini H, Nowroozzadeh MH, Salouti R, Nejabat M. Anti-VEGF therapy with bevacizumab for anterior segment eye disease. *Cornea* 2012;31:322-34.
20. Kim TI, Kim SW, Kim S, Kim T, Kim EK. Inhibition of experimental corneal neovascularization by using subconjunctival injection of bevacizumab (Avastin). *Cornea* 2008;27:349-52.
21. Chang JH, Garg NK, Lunde E, Han KY, Jain S, Azar DT. Corneal neovascularization: An anti-VEGF therapy review. *Surv Ophthalmol* 2012;57:415-29.
22. Padrini L, Isacchi B, Bilia AR, Pini A, Lanzi C, Masini E, *et al.* Pharmacokinetics and local safety profile of propranolol eye drops in rabbits. *Pediatr Res* 2014;76:378-85.

**Source of Support:** Nil. **Conflict of Interest:** None declared.