

General Characteristics of Eyelid Skin Morphological Alterations in Aging

Y. A. Yutskovskaya¹, O. N. Birko¹, I. V. Dyujzen², N. S. Chepurnova²,
E. V. Markelova², A. S. Yurlova²

¹Professor Yutskovskaya's clinic, Ltd, Vladivostok, Russia, ²FSBEI HE Pacific State Medical University of the Ministry of Health of the Russian Federation, Vladivostok, Russia

Abstract

Aim of the Investigation: Nowadays, eyelid skin is found to be subject to the destructive alterations well before than other facial areas. Skin restructuring changes, wherein lie visible signs of aging onset, are known to involve all the elements - epidermis, dermis, and subcutaneous deep tissues. Morphological skin condition estimation in females of different age groups based on the set of signs. **Materials and Methods:** Eyelid skin alteration comprehensive analysis has been conducted, taking into account patient's age, phototype, and aging morphological type. 60 females of three different photo- and morphotypes in three age groups have been examined: 20 females were 25–44 aged; 20–45–59 aged, and 20–60–74 aged. To examine structural and biochemical alteration in the skin tissues of the upper eyelid histological and immunohistological dyeing methods have been applied. The material has been statistically processed with the software package program “statgraphics.” **Results and Discussion:** Skin structural elements alterations in women are associated with the age, photo- and morphotype. Distinct skin structures are affected by the different factors. Starting at the age of 45–59 destructive eyelid skin alterations are dominating. Third skin phototype appeared to be the most sustainable toward aging. Each morphological aging type is contributing to the skin element alterations.

Key words: Destructive alterations, destructive eyelid skin, Skin aging

INTRODUCTION

Eyelid skin, by virtue of the characteristics of its innervation, increased mobility, as well as complex of external and internal destructive factors impact, is subject to the destructive alterations much earlier, than other facial areas. Inclusion of morphological, biochemical, and immunological specificities, which provide thinning, turgor and elasticity decline, water retention, and eyelid drooping development, is of great need to assess the cosmetological and surgical anti-aging effect tactics.^[1-3] In this, development of either of these esthetic eyelid problems is influenced by the number of genetic and epigenetic factors; those lead to the definite symptoms dominating in the overall picture of eyelid skin aging, which also should be taken into consideration in the long-term anti-aging skin rehabilitation program developing.^[4] Skin morphological alterations, leading to the visible aging sign development are known to involve all the elements - epidermis, dermis, and subcutaneous deep tissues.^[5] In doing so, skin morphological

condition integrative assessment could be performed only by the analysis of a number of indicators, under which thickness, layer numbers, and epidermis stratification, cellular and fibrillary components of superficial and deep dermis could be included.^[6] The aim of the investigation is eyelid skin alteration analysis, taking into account both evidence of tissue restricting morphological signs, and patient's age, phototype, and aging morphological type.

MATERIALS AND METHODS

60 females were under the investigation. All screened females were subdivided into 3 age groups according to the WHO classification (1 group – 25-44, 2 – 45-59, and 3 – 60-74 aged) and 3 groups, depending on the phototype

Address for correspondence:

Yutskovskaya Yana Alexandrovna, Professor
Yutskovskaya's clinic, Ltd", Vladivostok, Russia.
E-mail: pkuvl@mail.ru

Received: 07-06-2018

Revised: 22-06-2018

Accepted: 29-06-2018

(2, 3, and 4), and morphotype (deformation, muscular, and edematous) according to the I.I. Kolgunenko.^[4] Data have been estimated by means of morphometric analysis in different age groups, as well as based on aging type and skin phototype. Histological method and morphometric analysis method have been used to investigate different skin structures. To identify the elastic fibers distribution and structural features Weigert dyeing was used (Biovitrum, № 04-050802), collagen fibers coloring was carried out by means of Van Gieson's stains commercial kit (Biovitrum, № 04-051802) according to manufacturer's recommendations. Cell proliferative activity specificities (PCNA), enzyme distribution and activity of the intercellular matrix remodeling - matrix metalloproteinase 2 and 9 types (MMP2 and MMP9), their inhibitor TIMP2, as well as interleukins 1, 2, 6, and 10 have been studied in the parallel sections with the help of immunoperoxidase method. To do that, dewaxed sections have been soaked into the 3% hydrogen peroxide (to inhibit endogenous peroxidases) for 5 min and after 3-time rinsing in the phosphate buffered saline they have been placed for 1 h into the blocking solution, containing 2% bovine serum albumin, for blocking non-specific binding places with the antibodies. Incubation in the primary antibody solution has been performed for 12 h at +4°C, following 3-time rinsing in the phosphate buffered saline, after that sections have been placed into the species-specific biotinylated secondary antibody solution (PI-1000, goat anti-rabbit; PI-2000, goat anti-mouse, Vector Laboratories, 1:100). Processing with the secondary antibodies, streptavidin-peroxidase (Thermo Scientific), and chromogen (Peroxidase Substrate Kit, Vector Nova RED, SK-4800) have been carried out in compliance with the manufacturers' recommendations. To analyze tissue morphological alterations and to count immunopositive element number, preparations after chromogen staining have been counterstained with the hematoxylin-eosin or methyl green based on a standard methodology. All measurements have been carried out in the 10 non-overlapping viewpoints in each sample in the lens zoomx20. At least 5 cross-sections have been obtained for each marker from each sample. The material has been statistically processed with the software package program "statgraphics" by the variation statistic method with the use of Student's two-sample *t*-test. Chi-squared test (χ^2) has been used for the comparative analysis. Statistical shortfall, at which there was a rejection of the null hypotheses, was <0.05.

RESULTS AND DISCUSSION

Epidermis

In the group under the investigation mean epidermis layer thickness was about 15 mm, epithelium included 4-6 cell layers and thin stratum corneum. Along with what has been stated there have been samples, where thin epidermis (9-10 mm high) consisted only of 2-3 layers of the impressed epithelial cells with the thinnest stratum corneum, being

locally exfoliated [Figure 1a]. In cases of safe and even enlarged thickness in the eyelid skin epidermis, its inner structure has been changed markedly. The most common sign has been polarity cytodifferentiation damage with the expressed vacuolization and basal (germinative) layer cytoplasm cell dystrophy [Figure 1c] and/or superior layers [Figure 1d]. Resulting keratin layer structure has changed significantly - thickening, exfoliating, and loosening [Figure 1b].

Characteristics of eyelid skin cell elements in aging

Mean fibroblast allocation specific density in the deep dermis in the group under investigation was about 130 in 1,00,000 mm² [Figure 2a]. Deep dermis destruction and its cellular composition depletion (no more 90 fibroblasts in 1,00,000 mm²) have been noted fairly frequently [Figure 2b]. Very infrequently deep dermis has been characterized by the dense cellular composition among the safe structure of the intercellular substance - to 280-300 cells in 1,00,000 mm² [Figure 2c]. A separate variant of deep dermis structure could be considered that when there are severe disturbances of the fibrous tissue structure at high fibroblast content due to the expressed dermis edema and elastic frame destructions [Figure 2d and e].

Relatively safe fibroblast proliferative and synthetic characteristics have been evidenced in 3 phototype patients

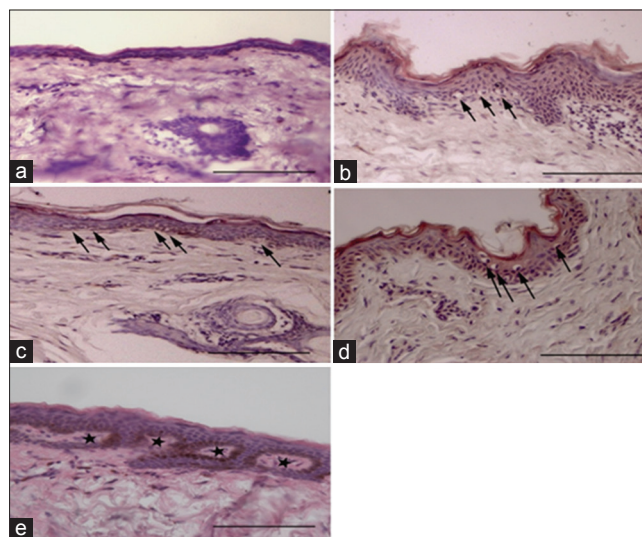


Figure 1: Thickness and epidermis structure alteration variants of the eyelid skin examined samples. (a) eyelid skin sample with the thin epidermis and thin dense stratum corneum, (b) significant thickening, polarity epidermis cytodifferentiation damage, increased keratinization and keratin layer loosening, and basal layer vacuolization changes (arrows). (c) Epidermis area with safe thickness and minor basal layer vacuolization signs (arrows). (d) granular layer vacuolization dystrophy. (e) Melanocyte locular aggregation in the deep skin layers (asterisks). Hematoxylin-eosin staining. Scale-100 mm

(mean 442 cells in 1,00,000 mm²) [Figure 3b] as well as in the deformation skin aging type onset (mean 597 cells in 1,00,000 mm²) [Figure 3c]. Age factor was essential for this factor while moving in elderly age group (60–74 aged) [Figure 3a].

Collagen fibers

In general, several types of collagen fibers distribution could be noted in the samples under investigation. The first variant - collagen fibers have a safe morphological structure, forming a dense net both in the superficial and deep dermis layers [Figure 4a]. In the case of more vivid aging processes superficial derma has relatively large distribution density of collagen fibers, but forms a clear border with a deep dermis, where fibers are fragmented, torn, with a heterogenic (thickened or thinned) structure and the connective tissue has significant areas without fibrous component [Figure 4b]. The third variant is considered as an example of a deep degenerative process characterized both by fibrillar component density decrease in the superficial dermis and collagenous framework radical destruction of the deep dermis [Figure 4c]. In this case, there is both specific density decrease of the collagenous fibers and their spatial orientation

disturbances. Another option of the collagen destruction is its full defragmentation and homogenization both in the superficial layers and in the deep dermis [Figure 4d]. Attention is drawn to the fact that regardless the depth disturbances of the collagenous fibers in the dermis tissues the most conserved collagenous framework remains in the subepithelial zone, perivascular sites, as well as in the bags of the hair follicles, and sebaceous glands [Figure 4e and f]. At the same time, it could be observed that homogeneous dense collagenous layer around these structures provides a strong connection with the surrounding connective tissue due to the numerous connective fibers of the different thickness and site density and dye affinity in collagenous fibers around skin derivatives appears to be higher, than in the interstitial fibers [Figure 4g].

Among scoping profiles, some advantage in the collagen safety is noted in 3 skin phototype patients [Figure 5b]. There is a tendency to reduce the collagen content in the superficial dermis as well as in the 45–59 aged, its level is statistically valid decreased in the elderly [Figure 5a]. Muscular aging type, as it is demonstrated on the Figure 5b, is characterized by more expressed collagen decrease.

while deep dermis collagen content analyzing, even more, pronounced patterns are defined [Figure 6].

Here, the age factor demonstrates statistically valid collagen content reduction [Figure 6a]. Collagen loss by the deep layers is more obvious in the muscular aging type [Figure 6c]. Collagen frame in the 3 skin phototype patients is noted to be the safest [Figure 6b].

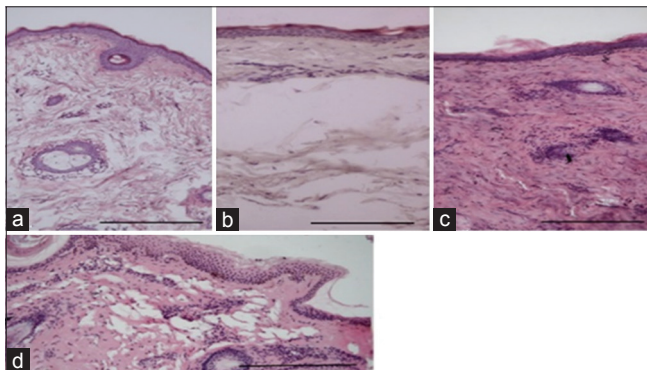


Figure 2: Eyelid skin deep dermis - different variants of the connective tissue and cellular content density. (a) The most typical variant of the morphological state for the samples under investigation. (b) Deep layer destruction simplification. (c) Safe deep dermis structure. (d) Dermis edema. Hematoxylin-eosin staining. Scale - 100 mm.

Elastic fibers

The most safe variant could be considered that one at which elastin distribution in the superficial dermis exceeds that in the deep dermis [Figure 7a-c]. In this, fiber morphology and topography are retained. The finest elastic fibers get the convoluted ways, form a dense network in the dermal layers and are linked with the epidermis basal membrane with the numerous binding elements [Figure 7b]. Elastin density in this is 70% in the superficial dermis and 18–22% in the deep

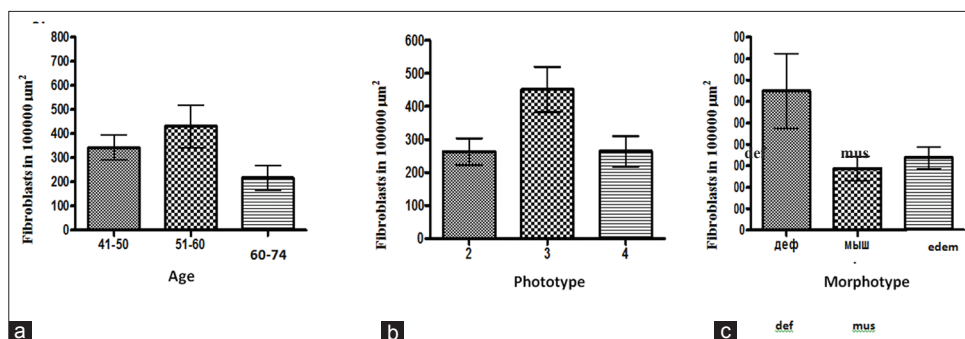


Figure 3: Fibroblast specific density distribution analysis in the superficial eye skin dermis in different age group patients (a), phototype (b), and aging morphotype (c) mm

dermis. Elastic fiber plexus in the deep dermis is concentrated around hair bags [Figure 7c]. Elastic frame of the subdermal arteries is detected as elastin area disposed along the

periphery of the elastin-secreting fibroblasts [Figure 7c]. More profound dermis elastin alteration is accompanied with the overall decline of its density as in the superficial, as in the deep layers. In this, there is an equalization of the morphometric indicators alongside the alignment of the visible layer boundary [Figure 7d and e]. As the destruction of elastin in the skin progresses, there are noticed alterations, presented at Figure 7f and g.

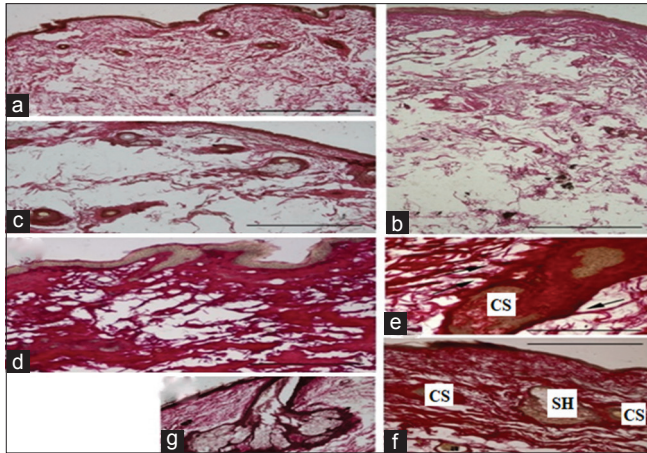


Figure 4: Eyelid skin collagen fiber structure and distribution characteristics in aging. (a) Minor fibrillary component decrease, (b) significant density decline of the collagenous fibers in the deep dermis in relative safety in the superficial layers, (c) fiber frame expressed degeneration both in the superficial and deep dermis, (d) edema and disintegration of the dermis collagenous fibers, and (e-g) characteristics of the fibrillary component distribution in the skin derivatives and around the blood vessels. The notation keys: hb- hair bag, sg - sebaceous gland, and a - artery. Arrows indicate binding fibers between the interstitial fibrous frame hair bag and hair bag collagen. Coloring was carried out by means of Van Gieson's stains. Scale - all - 100 mm, E - 50 mm.

A sudden transmission between superficial and deep dermis is noticed in the point, where elastic fibers practically disappear. In the deep skin layers, the only elastic fiber cluster locus is the hair structure where disparate and thickened elastic fiber bundles lacking in the characteristic tortuosity twine hair bag twice [Figure 7g]. Maximal elastic frame destruction is accompanied by elastin staining area decrease, fragmentation, and remaining elastic fiber destruction [Figure 7h]. In doing so, elastin accounts form more than 5% both in the superficial dermis and in its deep layers. Elastic frame irreversible destruction could be demonstrated through the absence of the specific dyeing in the subepithelial area and connective tissue hair bag. Short fragments of elastic fibers, lacking in the characteristic alignment and tortuosity, merely are present in the tissue [Figure 7i-l].

Elastic fibers content is detected to be the safest in the superficial dermis at the age of 45–59 in the 4 phototypes in a deformation aging type [Figure 8].

Deep dermis contains more safe elastin in 3 type patients and, to a greater extend, - in 4 phototype ones in the deformation aging morphotype [Figure 9].

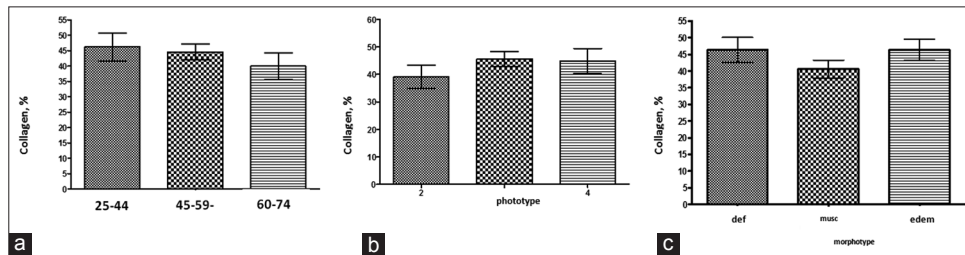


Figure 5: Collagen percentage in the superficial dermis of the eyelid skin in different aged patients (a), phototype (b), and aging morphotype (c)

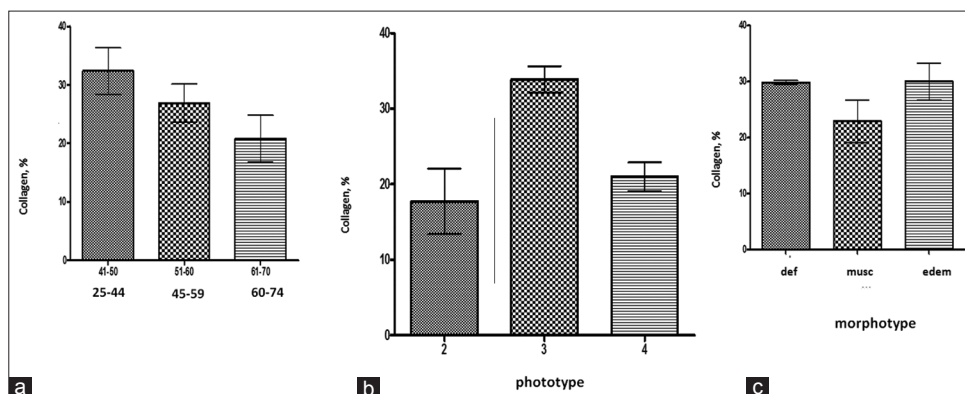


Figure 6: Deep dermis collagen content percentage in different aged patients' eyelid skin (a), phototype (b), and aging morphotype (c)

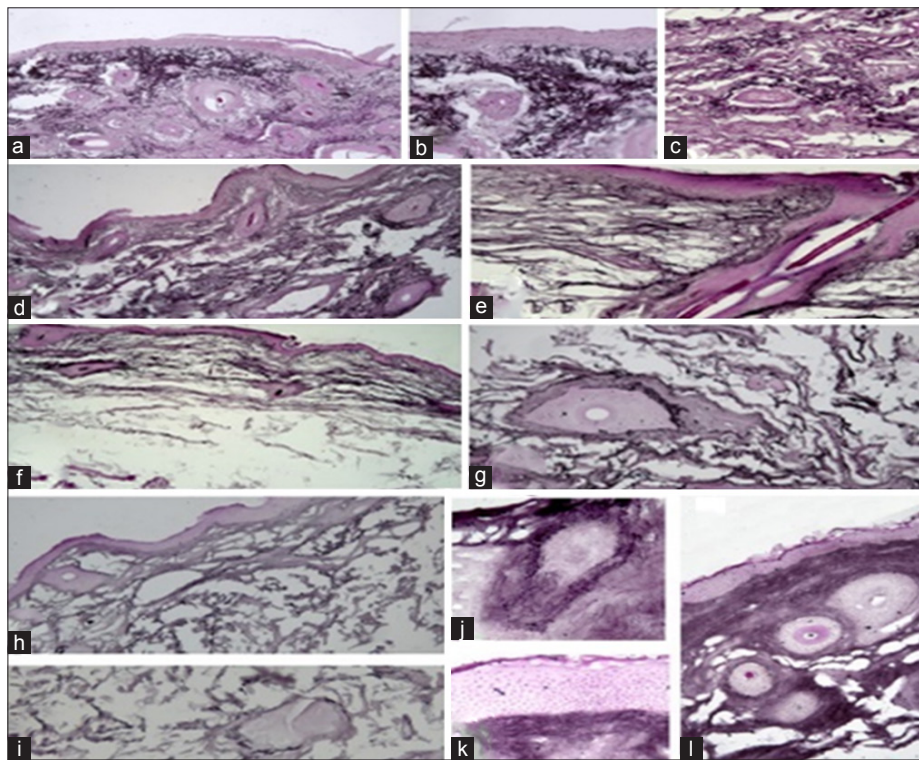


Figure 7: Structure and distribution characteristics of the eyelid skin elastic fibers in aging. a-c - The safest structure and distribution of the elastic fibers in the superficial (a and b) and deep (c) dermis. d and e - Alterations of the elastic frame in the superficial dermis. f and g - Expressed dystrophic processes of the elastic skin frame. Coloring is carried out by means of Weigert's stains. In the hair bag follicles (g) there is a maximal elastin concentration in the deepest sections. h and i - A maximal degree of elastic dermis component. j-l - A particular alteration form of the intercellular dermis matrix elastic component. Hair follicle (j) and area under the basal epidermis membrane (k) are the tissue areas, where fibrillary structure of the elastic matrix presents

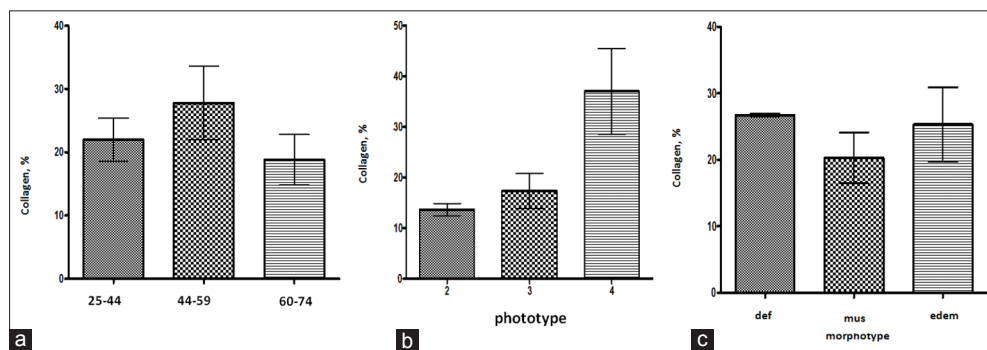


Figure 8: Elastin percentage in the eyelid skin superficial dermis in different aged patients (a), phototype (b), and aging morphotype (c)

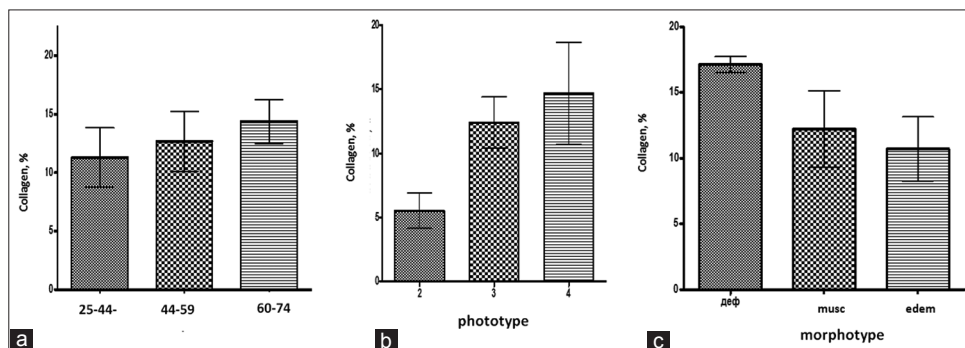


Figure 9: Elastin percentage in the eyelid skin deep dermis in different aged patients (a), phototype (b), and aging morphotype (c)

CONCLUSION

Thus, having analyzed eyelid skin alterations, it has been found that 3 phototypes are the safest, while 4 phototypes are safe to a lesser degree with a deformation aging, when there is a proliferative and synthetic fibroblast activity, content of the superficial and deep collagen and elastic fibers. Muscular morphotype is less favorable type of the morphological skin alterations.

REFERENCES

1. Zilberberg NV, Brill YA. Facial skin ageing: Questions and answers. *Status Praesens* 2015;2:112-8.
2. Zolotenkova GV, Morosov YE, Tkachenko SB, Pigolkin YI. Ageing alterations of the structural-functional skin characteristics. *Vestnikbaltijskog ofederalnogouniversitetaim. I. Kanta. Series Exp Med Sci* 2014;1:132-9.
3. Cheluyko SS, Maluk EA, Korneeva LS, Krasavina NP. Skin dermis morph functional characteristics and its alterations in ageing (literature review). *Bulutenfiziologiiipatologiidyhaniya* 2016;60:111-6.
4. Zolotenkova GV, Morosov YE, Tkachenko SB, Pigolkin YI. Ageing alterations of the structural-functional skin characteristics. *Vestnikbaltijskog ofederalnogouniversitetaim. I. Kanta. Series Exp Med Sci* 2014;1:132-9.
5. Karaulov AV, Bykov SA, Bykov AS. Immunology, Microbiology and Skin Immunopathology. Moscow: Russia b Medical Faculty; 2012. p. 328.
6. Tatuzyan EG, Belovol AN, Tkachenko SG. Appropriate treatment of the facial skin ageing alteration. *Dermatol Venerol* 2014;4:100-8.

Source of Support: Nil. **Conflict of Interest:** None declared.