

# Acne: An Ignored Dermal Malady

Shashi Kiran Misra<sup>1</sup>, Nisha Sharma<sup>1</sup>, Arpit Katiyar<sup>2</sup>, Umansh Narayan Awasthi<sup>2</sup>,  
Anupriya Kapoor<sup>1\*</sup>

<sup>1</sup>Department of Pharmaceutical Sciences, School of Pharmaceutical Sciences, Chhatrapati Shahu Ji Maharaj University, Kanpur, Uttar Pradesh, India, <sup>2</sup>Department of Pharmacy, Sai Meer College of Pharmacy, Kannauj, Uttar Pradesh, India

## Abstract

Acne vulgaris is a dermal inflammatory condition that originates as a result of clogging of the pilosebaceous unit and is a complicated skin ailment that affects over 85% of young people around the world. The disorder has a crucial impact on a patient's life quality. The causative bacterium for acne is *Propionibacterium acne*. The article emphasizes on the prime factors responsible for the occurrence of acne and also highlights the various forms of acne, types of scars and clinical diagnosis for the same. Various options for the management of acne including topical agents, oral antibiotics, and therapies along with preventive methods are discussed in the article.

**Key words:** Acne, pilosebaceous, *Propionibacterium acne*, scars, topical agents

## INTRODUCTION

Acne vulgaris is a complicated skin ailment that affects over 85% of young people around the world. Although it typically appears during puberty and worsens throughout adolescence, epidemiological studies suggest that it can turn out at any stage.<sup>[1]</sup> The first medical monograph on acne was published in the United States in 1885. Acne, also commonly referred to as pimple, is a prevalent skin disorder that is characterized by the presence of clogged hair follicles that are blocked due to the presence of dead skin cells, bacteria, oil, and sebum. According to the report, India observes roughly 8–10 million new cases each year.<sup>[2]</sup>

Acne is a chronic inflammatory disease of the pilosebaceous unit that affects areas such as the face, chest, and back. The causative bacteria for acne are *Propionibacterium acne*, which is an example of slow-growing, aero-tolerant anaerobic Gram-positive bacteria,<sup>[3]</sup> the same is also responsible for the occurrence of chronic blepharitis and endophthalmitis. The bacteria metabolize the triglycerides present in the sebum and thereby result in the production of free fatty acids that consequently results in the stimulation of release of mediators that are responsible for inflammation. Even though acne leaves scars and has an impact on self-esteem and body image, it is commonly ignored in dermatological treatment.<sup>[4]</sup> However, in the case of facial acne, it appears clear that detecting the disease early will allow

treatment to begin on time, preventing it from progressing and causing medical and psychological consequences.<sup>[5]</sup>

The therapy involved in the treatment of acne is a common issue that dermatologists and general practitioners face. Although the presence of acne is not a severe or life-threatening condition, it can have a bleak outcome on a patient's quality of life because it frequently arises throughout puberty and adolescence, which is a vulnerable time in life. Persistent acne lesions may eventually result in permanent scarring.<sup>[6]</sup>

The pathogenesis of acne includes four primary processes: Hyperkeratinization of pilosebaceous follicles, increased sebum production, increased *P. acnes* colonization, and inflammation. Recently, there has been a surge in acne treatments that involves a change in regular routines such as facial washing, and the use of specific facial cleansers.<sup>[7,8]</sup>

## INFLAMMATORY MEDIATORS<sup>[9,10]</sup>

The inflammatory mediators involved in the pathogenesis of acne are displayed in Figure 1.

### Address for correspondence:

Dr. Anupriya Kapoor, Department of Pharmaceutical Sciences, School of Pharmaceutical Sciences, Chhatrapati Shahu Ji Maharaj University, Kanpur, Uttar Pradesh, India. E-mail: anupriya321@gmail.com

**Received:** 17-01-2022

**Revised:** 28-06-2022

**Accepted:** 21-07-2022

## TYPES OF ACNE

### Non-inflammatory acne

Whiteheads are prominent examples of acne that are non-inflammatory. They are comedones that are formed as a result of oil and dead skin cells accumulating on the surface of the skin and are commonly present on the face, shoulder, neck, and chest.<sup>[11,12]</sup> The major factors responsible for the occurrence of the same include hormonal fluctuations, hereditary factors, puberty, and lifestyle changes. Blackheads are similar to whiteheads in appearance. They are comedones that are not closed. There is no skin covering the sebum that has been accumulated. They are exposed to the outside world and then oxidized. As a result, they saw black and dubbed it blackheads.<sup>[13]</sup> The prominent reasons for the prevalence of blackheads comprise hormonal fluctuations, intake of corticosteroids, lithium, androgens, and production of excessive oil by the body, etc.

### Inflammatory acne

Papules are the type of acne that is characterized as reddish lesions that are found on the skin due to clogged pores. Papules form when excess oil, germs, and dead skin cells penetrate the skin's deeper layers, irritating. Our skins become red and swollen, a condition known as red inflammatory papules.<sup>[14]</sup> The factors that trigger the papule breakouts include diet enriched with carbohydrates, stress, and hormonal changes.

Pustules are pus-filled acne that is either red bumps with a whitish center or white bumps that are hard. Pustules are formed when the walls of clogged pores begin to rupture or break down as an impact pustules are larger as compared to whiteheads and blackheads. They are distributed in the face, neck, chest, hairline, pubic areas, etc., the pathological conditions that lead to pustules include psoriasis, rosacea, chickenpox, IgA pemphigus, and smallpox.

Cysts are more serious than typical pimples because they develop deep within the skin. Because the pores got plugged, more infection and suffering ensued. People with oily skin types are more prone to the prevalence of the same.

Inflammatory mediators		
<b>Epithelium derived</b>	<b>Sebum derived</b>	<b>Propionibacterium acne derived</b>
Interlukins	Fatty acids	Lipase chemotactic factor
Tumornecrosis factors		Peptide chemotactic factor
		Histamine
		Prostaglandins

**Figure 1:** Inflammatory mediators involved in the pathogenesis of acne

Nodular acne is considered to be one of the most severe forms of acne that are red in appearance.<sup>[15,16]</sup> The chief difference between nodules and other forms of acne comprises the fact that the treatment of nodules is not possible by the use of simple over-the-counter drugs and may persist for weeks to months. Figure 2 reflects the various types of acne.

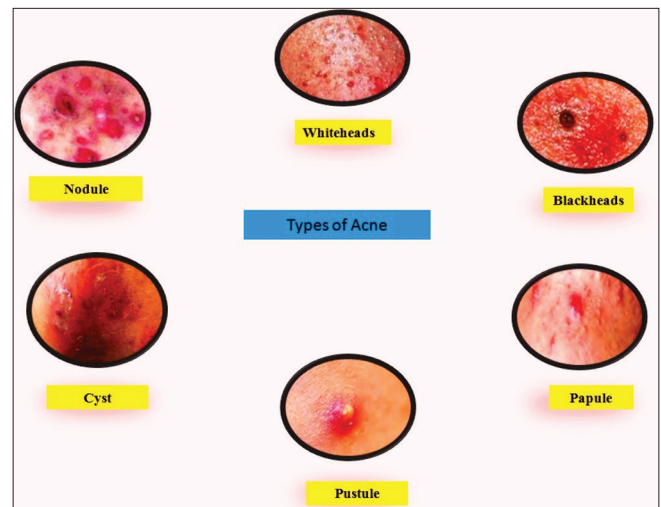
## UNDERLYING RISK FACTORS FOR THE DEVELOPMENT OF ACNE<sup>[17-19]</sup>

Numerous myths prevail about the reasons that contribute to the development of acne. It is a common belief that the consumption of food rich in oil, carbohydrates, and spices results in acne. While there are no rigid specific scientific facts for the above-mentioned reason, however, certain risk factors for the development of acne are

1. Hormonal changes at the time of puberty and pregnancy
2. Consumption of birth control pills and corticosteroids
3. Intake of a diet rich in refined sugar and carbohydrates
4. Excessive production of oil and sebum
5. Fluctuation in hormone level at the time of menstruation
6. Excessive cleaning and pressure applied to remove debris from the skin
7. Helmet's chin straps, collars, suspenders, and other similar items can worsen acne in some patients
8. Pseudofolliculitis; also known as razor bumps or razor rash, is a condition that causes sensitive pimples on the skin of acne sufferers who shave with a razor
9. Drugs such as prednisone, Deltasone, Orasone, prednisone-M, liquid red, or steroids may induce or exacerbate acne.

## THE SEVERITY GRADING SYSTEM FOR ACNE<sup>[20,21]</sup>

For the evaluation of the efficiency of treatment and epidemiological purposes, it is essential to determine the



**Figure 2:** Types of acne

severity of acne. Although, acne vulgaris has remained one of the most common dermatological conditions treated by physicians. The need for grading was first felt in the 1950s. Grading includes subjective methods that involve the determination of the severity of acne. The method is based on clinical examination and lesion counting, which is performed by utilizing instruments such as photography, fluorescent photography, and polarized light photography. The global grading system for acne is given in Table 1. Each type of lesion is given a value depending on severity; Table 2 gives the relation between type of lesion and value. The score for each area is calculated using the formula

$$\text{Local score} = \text{Factor} \times \text{Grade} (0-4)$$

A score of 1–18 is referred to as mild; 19–30, moderate; 31–38, severe; and >39, very severe. Figure 3 gives the schematic illustration of the severity of acne.

## FORMS OF ACNE SCARS

In the vast majority of cases, acne affects the facial skin, with many patients suffering from scarring, the severity of which is related to acne grade. Acne scars are a result of the faulty wound healing response to cutaneous inflammation, with inflammatory cell infiltrates present in nearly 80% of atrophic scars. Papules and pustules are the sources of almost all scars (99%). (Inflammatory lesions) and post-inflammatory lesions.<sup>[24-26]</sup> Early lesions elicit a significant, nonspecific immune response in patients who are not prone to scarring, which lessens as the lesions heal. Early lesions in scarring patients, on the other hand, are characterized by a lower number of skin-homing CD4+ T-cells than in

**Table 1: Global grading system<sup>[22]</sup>**

Location	Factor
Forehead	2
Right cheek	2
Left cheek	2
Nose	1
Chin	1
Chest and upper back	3

**Table 2: The relation between type of lesion and value<sup>[23]</sup>**

Value of severity	Type of lesion
0	No lesion
1	Comedones
2	Papule
3	Pustule
4	Nodule

non-scarring patients, a response that becomes more active in resolving lesions.<sup>[24]</sup> Figure 4 gives a pictorial representation of various forms of acne scars and a description of various forms of acne is presented in Table 3.

## CLINICAL DIAGNOSIS<sup>[29-31]</sup>

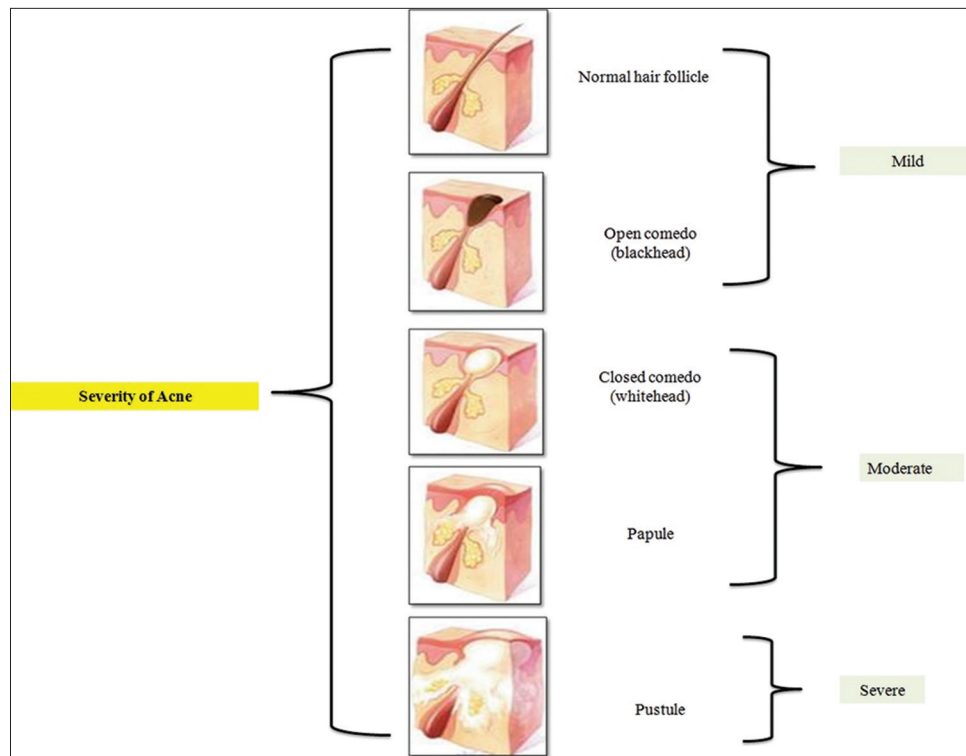
Acne vulgaris is diagnosed mostly through clinical examination. Folliculitis, keratosis pilaris, perioral dermatitis, seborrheic dermatitis, and rosacea are all typical acne differential diagnoses. An underlying cause of acne, such as an aggravating drug or an endocrinologic condition producing hyperandrogenism (e.g., polycystic ovarian syndrome); can be determined through history and physical examination. Seborrhea, hirsutism, and androgenetic alopecia are further dermatologic symptoms of androgen excess. For women who have normal menstrual cycles, endocrinologic testing is not frequently ordered. Older women, particularly those with new-onset acne and other signs of androgen excess (e.g., hirsutism, androgenic alopecia, menstrual irregularities, and infertility), should have their total and free serum testosterone, dehydroepiandrosterone, and luteinizing and follicle-stimulating hormone levels tested for androgen excess.<sup>[25]</sup> The various clinical diagnoses for acne and their differentiating characteristics are depicted in Table 4.

## ACNE MIMICKING DISEASES<sup>[35]</sup>

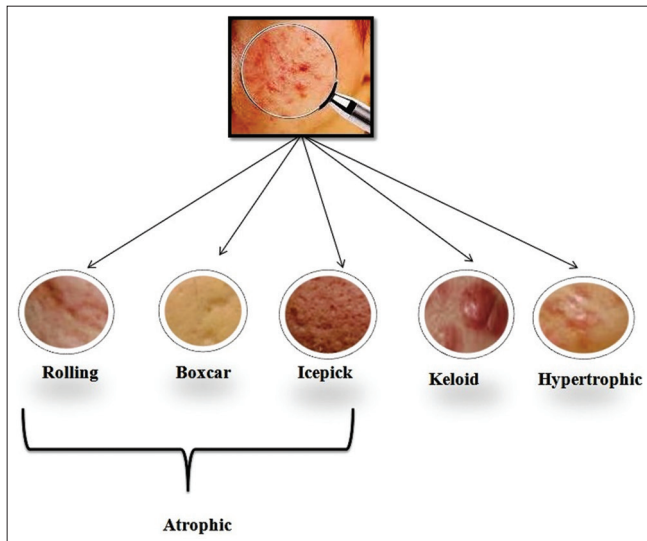
The absence of response toward the treatment regimen despite good patient compliance is the situation that calls for the alteration in the treatment regimen as certain pathological conditions mimic the symptoms of acne but require other specific treatment options. Examples of such situations include diseases such as Nevus comedonicus, Favre Racouchat Syndrome, Rosacea, Perioral dermatitis, Acne agminata, and Chloracne.

## TREATMENT OF ACNE

Acne being the eighth most prevalent disease across the globe affects nearly 9.4% of the total world population.<sup>[36]</sup> The treatment of acne depends on the severity of the condition; the health-care provider may recommend the use of over-the-counter drugs in mild-to-moderate situations while the severe category of infection requires stringent treatment since the situation is associated with physical and physiological morbidity. Several treatment options are available that can aid in designing a suitable regimen for the patient with the common objective of reduction of inflammation, reduction in the production of sebum, and reduction in hyperproliferation of follicular epithelial cells.



**Figure 3:** Schematic illustration of the severity of acne



**Figure 4:** Various forms of acne scars

## TREATMENT OPTIONS

### Topical agents

The selection of topical agent depends on the age of the patient, severity of acne, site of acne, etc., several options available for the topical management of acne include drugs such as retinoids such as adapalene, isotretinoin, tretinoin, retinoyl- $\beta$ -glucuronide, tazarotene, and tretinoin.<sup>[37]</sup> Antibiotics such as clindamycin and erythromycin are also found to be effective since there is a risk of the development of bacterial resistance with antibiotic monotherapy. Antibiotics

should be preferably used in combination with benzoyl peroxide due to their capacity to significantly reduce *P. acnes* and inflammatory acne lesions, as well as moderately diminish non-inflammatory acne lesions. Other options include the use of azelaic acid, benzoyl peroxide, chemical peels, corticosteroids, dapsone, hydrogen peroxide, niacinamide, and salicylic acid.<sup>[38]</sup>

### Oral medications

For moderate-to-severe conditions, oral antibiotics have proved their efficacy in the reduction of infection. The choice of antibiotics includes the drugs such as tetracycline and macrolides.<sup>[39]</sup> The prime consideration with antibiotic treatment is the duration of treatment; the duration should be short since long-term consumption of antibiotics results in the emergence of microbial resistance. Oral contraceptives are also used among women who also wish to opt for contraception. The usual combination of contraceptive contains estrogen and progestin, the common side effect encountered with the consumption of oral contraceptive includes weight gain, breast tenderness, and nausea. Drugs such as spironolactone are also found to be beneficial for women who have failed to respond to antibiotics. Vitamin A derivative isotretinoin has also proved to be effective in the treatment of acne.<sup>[40]</sup>

### Therapies

A wide variety of therapies either alone or in conjunction with drugs is found to be effective in the treatment of acne.



**Table 3:** Description of various forms of acne<sup>[27,28]</sup>

Description of various forms of acne scars	
Atrophic scars	Inflammatory mediators and enzymatic breakdown of collagen fibers and subcutaneous fat are most likely to blame. The most basic and practical classification scheme splits atrophic acne scars into three categories: Icepick, rolling, and boxcar scars are all examples of scars.
Ice pick	Icepick scars are deep, sharply margined epithelial traits that extend vertically to the deep dermis or subcutaneous tissue and are narrow (<2 mm).
Rolling	Rolling scars are typically wider than 4 to 5 mm and result from dermal tethering of otherwise normal-appearing skin.
Boxcar	Boxcar scars resemble varicella scars in that they are circular to oval depressions with highly marked vertical borders.
Hypertrophic scars	These elevated scars appear on the chest, back, or shoulders, especially in acne sufferers. They appear when too much connective tissue is formed during the healing process of a wound.
Keloid scars	Keloids develop as the consequence of improper wound healing caused by skin damage or inflammation. Keloid formation is influenced by both hereditary and environmental factors. When too much connective tissue is produced, keloid scars occur. This is a very uncommon type of acne scarring. Keloids have an unregulated fibroblastic phase, which results in clinical and histological abnormalities.

Light therapy, chemical peels containing retinoic acids, glycolic acid, etc. methods like drainage and extraction, and steroidal injections have proved their benefits in the treatment of dermal issues that originated as a consequence of acne.<sup>[41]</sup>

## PREVENTION OF ACNE

The link between nutrition and acne is a topic of debate. Several new types of research in the past 10 years have prompted doctors to consider whether there is a connecting link between nutrition and acne. Milk and dairy products, chocolate, the glycemic load of the diet, dietary fiber, fatty acids, antioxidants, zinc, Vitamin A, and iodine are some of the dietary components that influence the course of acne vulgaris.<sup>[42]</sup>

1. Milk and dairy products: A high intake of full-fat dairy products (more than two glasses per day) was linked to moderate-to-severe acne. Acne that develops after consuming iodine-rich meals arises rapidly and is characterized by many papules. The iodine component of milk may potentially play a role in the acne-milk connection.<sup>[43]</sup>
2. Chocolate Restriction: When human blood mononuclear cells were stimulated with *P. acnes*, chocolate-eating prepared them to release more pro-inflammatory cytokines, interleukin-1, and TNF. Dark chocolate has more antioxidants than milk chocolate, implying that it has fewer comedogenic effects. Some people claim that avoiding meat, milk, and chocolate improves their skin.<sup>[44]</sup>
3. Dietary Fiber: Patients with AV who ate 30 g of high-fiber breakfast cereal per day (13 g of fibers per serving) saw a significant improvement in their skin condition.

Increased bacterial bulk is promoted by high fiber consumption, but the microflora makeup is unaffected. In contrast, good digestion improves acne conditions. Gastrointestinal dysfunction is a major risk factor for sebaceous gland illnesses and is linked to their occurrence and progression. Abdominal bloating, in particular, was found to be 37% more likely to be linked to acne and other seborrheic illnesses.<sup>[45]</sup>

4. Antioxidants: Polyphenols are antioxidant compounds that can be found in a variety of foods, such as nuts, fruits, vegetables, chocolate, wine, and tea. Antimicrobial, anti-inflammatory, and anti-cancer effects are all found in polyphenols.<sup>[46]</sup>
5. Frequent Cleansing and Sun Protection: Washing and over-the-counter cleansers are frequent acne vulgaris treatments, although the clinical evidence for their efficacy is unclear. Cleansers reduced the number of inflammatory and non-inflammatory acne lesions, suggesting that they could be useful for acne treatment.<sup>[42]</sup> Acne sufferers should use soap-free washing solutions with a pH close to that of their skin (5.5). For women, a pH range of 4.5–5.5 was regarded normal, while for men, a pH range of 4–5.5 was deemed normal. Lowering pH decreases the inflammatory TH2 response (CD4+ cells orchestrate protective Type 2 immune responses) and speeds up barrier function recovery, reducing epidermal hyperproliferation, according to studies.<sup>[47]</sup>
6. Avoid Stress and Tobacco: Stress has been linked to the development of AV pathology. Several cutaneous neurogenic factors interact with a pathogenic cascade in acne to explain the link between emotional stress and the onset or exacerbation of acne. Stress increases cortisol levels by triggering the release of pro-inflammatory cytokines and CRH.<sup>[48]</sup> The comedonal type, which is defined by the presence of micro and macro comedones

**Table 4:** Clinical diagnosis of acne and their differentiating characteristics<sup>[32-34]</sup>

Clinical diagnosis of acne	
Diagnosis	Differentiating characteristics
Bacterial folliculitis	Spontaneous eruption; spreads by scratching or shaving; sporadic distribution. Acne vulgaris can develop as inflammatory erythematous papules, pustules, or nodules, and it can be difficult to discriminate.
Acne keloidalis nuchae	Lesions limited to the posterior neck; initially, papules and pustules that may proceed to confluent keloids; commonly encountered in black people.
Acneiform eruptions	Secondary to systemic drugs, topical corticosteroids, contrast dye, and cosmetic cosmetics; onset and association with exposure may be abrupt; relief with cessation of exposure.
Chloracne	Comedones, pustules, and cysts in the post-auricular area, axillae, and groynes; halogenated aromatic hydrocarbons exposure history; the patient may have other systemic signs
Favre-Racouchot	Patients are usually older and have a history of extensive sun exposure. Open and closed comedones on the periorbital and malar areas; no inflammatory lesions; patients are usually older and have a history of significant sun exposure.
Periorificial dermatitis	Topical corticosteroid usage often exacerbates papules and pustules in the periorificial distribution.
Miliaria	Heat rash; non-follicular papules, pustules, and vesicles in response to effort or heat exposure. Miliaria is a medical condition. Dermoscopy, which reveals huge white globules with darker halos around them, has been proven to be a valuable tool, especially in those with darker skin (white bullseye). If in doubt, a skin punch biopsy might be used to aid in diagnosis.
Perioral dermatitis	Papules and pustules on the chin and nasolabial folds, with a clear zone around the vermilion border.
Adenoma sebaceum	Multiple lesions associated with tuberous sclerosis; skin biopsy test findings demonstrate dermal fibrosis and vascular proliferation and dilatation; little waxy papules over the medial cheekbones, nose, and forehead; multiple lesions associated with tuberous sclerosis; (angiofibroma). Multiple endocrine neoplasia type I and, in rare cases, Birt-Hogg-Dubé syndrome can both cause facial angiofibroma.
Rosacea	No comedones; erythema and telangiectasias. Rosacea can affect the eyes, as well as a prominent nose. Acne is most common in teenagers, although rosacea appears considerably later in life. In addition, unlike rosacea patients, blackheads are widespread, and bumps and pimples on the trunk and arms are common.
Seborrheic dermatitis	Scales that are greasy and yellow-red coalesce into macules or papules. On the brows, glabella, paranasal skin, nasolabial folds, beard, scalp, and chest, seborrheic dermatitis manifests as ill-defined erythematous areas with oily scale. Because of its efficiency in treating concurrent rosacea and acne, azelaic acid may be especially useful in this application.

and minimal inflammatory lesions, is more common among smokers, prompting the authors to coin the term “smoker’s face.” Nicotine stimulates acetylcholine, which stimulates the sebaceous gland. Smokers had a 2.6–6.3 times higher chance of being afflicted by present acne than nonsmokers among patients with adolescent acne<sup>[49,50]</sup>

## CONCLUSION

Acne is a common pathological dermal disorder that has a pathological and psychological impact. There are various management options available in the market that if used appropriately can reduce the incidence of scars developed as a consequence of acne. It would be an appropriate judgment to opt for combination therapy instead of monotherapy.

## ACKNOWLEDGMENT

The authors would like to acknowledge the School of pharmaceutical sciences, CSJM University, Kanpur, India for the infrastructure support.

## COMPLIANCE WITH ETHICAL STANDARDS

The article does not contain clinical studies or patient’s data.

## AUTHOR CONTRIBUTION

All authors have made substantial efforts for the compilation of the article. AK and SKM drafted the article and critically

evaluated the contents. All authors have agreed to be accountable for all the aspects of work.

## REFERENCES

- De Sousa IC. New and emerging drugs for the treatment of acne vulgaris in adolescents. *Expert Opin Pharmacother* 2019;20:1009-24.
- Riley WT, Oh A, Aklin WM, Wolff-Hughes DL. National institutes of health support of digital health behavior research. *Health Educ Behav* 2019;46 Suppl 2:12S-9.
- Nast A, Dreno B, Bettoli V, Degitz K, Erdmann R, Finlay AY, *et al.* European evidence-based (S3) guidelines for the treatment of acne. *J Eur Acad Dermatol Venereol* 2012;26 Suppl 1:1-29.
- Tan J, Thiboutot D, Popp G, Gooderham M, Lynde C, Del Rosso J, *et al.* Randomized phase 3 evaluation of trifarotene 50 µg/g cream treatment of moderate facial and truncal acne. *J Am Acad Dermatol* 2019;80:1691-9.
- Haider A, Shaw JC. Treatment of acne vulgaris. *JAMA* 2004;292:726-35.
- Tan JK, Tang J, Fung K, Gupta AK, Thomas DR, Sapra S, *et al.* Development and validation of a scale for acne scar severity (SCAR-S) of the face and trunk. *J Cutan Med Surg* 2010;14:156-60.
- Bellew S, Thiboutot D, Del Rosso JQ. Pathogenesis of acne vulgaris: What's new, what's interesting and what may be clinically relevant. *J Drugs Dermatol* 2011;10:582-5.
- Purvis D, Robinson E, Watson P. Acne prevalence in secondary school students and their perceived difficulty in accessing acne treatment. *N Z Med J* 2004;117:U1018.
- Al-Natour SH. Acne mimickers: Another cause for unresponsive acne. *J Saudi Soc Dermatol Dermatol Surg* 2012;16:35-40.
- Webster GF. Acne. *Curr Probl Dermatol* 1996;8:237-68.
- White GM. Recent findings in the epidemiologic evidence, classification, and subtypes of acne vulgaris. *J Am Acad Dermatol* 1998;39:S34-7.
- Wat H, Wu DC, Rao J, Goldman MP. Application of intense pulsed light in the treatment of dermatologic disease: A systematic review. *Dermatol Surg* 2014;40:359-77.
- Khan K, Karodi R, Siddiqui A, Thube S, Rub R. Development of anti-acne gel formulation of anthraquinones rich fraction from *Rubia cordifolia* (*Rubiaceae*). *Int J Appl Res Nat Prod* 2011;4:28-36.
- Aruna MS, Sravani A, Reshma V, Priya NS, Prabha MS, Rao NR. Formulation and evaluation of herbal acne gel. *World J Pharm Res* 2015;4:2324-30.
- Patil SC, Gadade DD, Rathi PB. Design, development and evaluation of herbal gel for treatment of psoriasis. *J Innov Pharm Biol Sci* 2015;2:72-87.
- Magin P, Pond D, Smith W, Watson A. A systematic review of the evidence for "myths and misconceptions" in acne management: Diet, face-washing and sunlight. *Fam Pract* 2005;22:62-70.
- Son BK, Yun Y, Choi IH. Efficacy of ah shi point acupuncture on acne vulgaris. *Acupunct Med* 2010;28:126-9.
- Enshaieh S, Jooya A, Siadat AH, Iraj F. The efficacy of 5% topical tea tree oil gel in mild to moderate acne vulgaris: A randomized, double-blind placebo-controlled study. *Indian J Dermatol Venereol Leprol* 2007;73:22.
- Goulden V, McGeown CH, Cunliffe WJ. The familial risk of adult acne: A comparison between first-degree relatives of affected and unaffected individuals. *Br J Dermatol* 1999;141:297-300.
- Chalyk N, Klochkov V, Sommereux L, Bandaletova T, Kyle N, Petyaev I. Continuous dark chocolate consumption affects human facial skin surface by stimulating corneocyte desquamation and promoting bacterial colonization. *J Clin Aesthet Dermatol* 2018;11:37.
- Mahmood NF, Shipman AR. The age-old problem of acne. *Int J Womens Dermatol* 2017;3:71-6.
- Poster A, Melnik BC, John SM, Carrera-Bastos P, Cordain L. Hair Loss Help Hair Loss Open Topic Dairy Products (Milk) and Hair Androgen Receptor Relationship. *Post Dairy Studies Here: New York times*; 2010.
- Sutaria AH, Masood S, Schlessinger J. *Acne Vulgaris*. Treasure Island, FL: StatPearls Publishing; 2020.
- Kraft J, Freiman A. Management of acne. *CMAJ* 2011;183:E430-5.
- Elliott C. Risk benefit analysis of treatments for cystic acne. In: An Honors Thesis Presented to the University Honors Program Gardner-Webb University; 2019.
- Stolla S, Shalita AR, Webster GF, Kaplan R, Danesh S, Penstein A. The effect of the menstrual cycle on acne. *J Am Acad Dermatol* 2001;45:957-60.
- Titus S, Hodge J. Diagnosis and treatment of acne. *Am Fam Physician* 2012;86:734-40.
- Sun KL, Chang JM. Special types of folliculitis which should be differentiated from acne. *Dermatoendocrinology* 2017;9:e1356519.
- Bikowski J. Facial seborrheic dermatitis: A report on current status and therapeutic horizons. *J Drugs Dermatol* 2009;8:125-33.
- Dréno B, Bissonnette R, Gagné-Henley A, Barankin B, Lynde C, Kerrouche N, *et al.* Prevention and reduction of atrophic acne scars with adapalene 0.3%/benzoyl peroxide 2.5% gel in subjects with moderate or severe facial acne: Results of a 6-month randomized, vehicle-controlled trial using intra-individual comparison. *Am J Clin Dermatol* 2018;19:275-86.
- Connolly D, Vu HL, Mariwalla K, Saedi N. Acne scarring pathogenesis, evaluation, and treatment options. *J Clin Aesthet Dermatol* 2017;10:12.
- Gan SD, Graber EM. Popular scars: An addition to the acne scar classification scheme. *J Clin Aesthet Dermatol* 2015;8:19.
- Elliott C. Risk Benefit Analysis of Treatments for Cystic Acne. Undergraduate Honors Theses; 2019.
- Fife D. Practical evaluation and management of atrophic

- acne scars: Tips for the general dermatologist. *J Clin Aesthet Dermatol* 2011;4:50.
35. Ni C, Chiu MW. Psoriasis and comorbidities: Links and risks. *Clin Cosmet Investig Dermatol* 2014;7:119.
  36. Fox L, Csongradi C, Aucamp M, Du Plessis J, Gerber M. Treatment modalities for acne. *Molecules* 2016;21:1063.
  37. Ulvestad M, Bjertness E, Dalgard F, Halvorsen JA. Acne and dairy products in adolescence: Results from a Norwegian longitudinal study. *J Eur Acad Dermatol Venereol* 2017;31:530-5.
  38. Kucharska A, Szmurło A, Sińska B. Significance of diet in treated and untreated acne vulgaris. *Adv Dermatol Allergol* 2016;33:81.
  39. Zhang H, Liao W, Chao W, Chen Q, Zeng H, Wu C, *et al.* Risk factors for sebaceous gland diseases and their relationship to gastrointestinal dysfunction in Han adolescents. *J Dermatol* 2008;35:555-61.
  40. Draelos ZD. The effect of a daily facial cleanser for normal to oily skin on the skin barrier of subjects with acne. *Cutis* 2006;78 Suppl 1:34-40.
  41. Prakash C, Bhargava P, Tiwari S, Majumdar B, Bhargava RK. Skin surface pH in acne vulgaris: Insights from an observational study and review of the literature. *J Clin Aesthet Dermatol* 2017;10:33.
  42. Albuquerque RG, Rocha MA, Bagatin E, Tufik S, Andersen ML. Could adult female acne be associated with modern life? *Arch Dermatol Res* 2014;306:683-8.
  43. Yang YS, Lim HK, Hong KK, Shin MK, Lee JW, Lee SW, *et al.* Cigarette smoke-induced interleukin-1 alpha may be involved in the pathogenesis of adult acne. *Ann Dermatol* 2014;26:11-6.
  44. Kim MR, Kerrouche N. Combination of benzoyl peroxide 5% gel with liquid cleanser and moisturizer SPF 30 in acne treatment results in high levels of subject satisfaction, good adherence and favorable tolerability. *J Dermatol Treatment* 2018;29:49-54.
  45. Kircik LH. The role of benzoyl peroxide in the new treatment paradigm for acne. *J Drugs Dermatol* 2013;12:s73-6.
  46. Leyden JJ, Del Rosso JQ. The effect of benzoyl peroxide 9.8% emollient foam on reduction of *Propionibacterium* acnes on the back using a short contact therapy approach. *J Drugs Dermatol* 2012;11:830-3.
  47. Dréno B, Layton A, Zouboulis CC, Lopez-Estebarez JL, Zalewska-Janowska A, Bagatin E, *et al.* Adult female acne: A new paradigm. *J Eur Acad Dermatol Venereol* 2013;27:1063-70.
  48. Aoki S, Nakase K, Hayashi N, Noguchi N. Transconjugation of erm (X) conferring high-level resistance of clindamycin for *Cutibacterium* acnes. *J Med Microbiol* 2019;68:26-30.
  49. Amar L, Kircik LH. Treatment of moderate acne vulgaris in Fitzpatrick skin Type V or VI: Efficacy and tolerability of fixed combination clindamycin phosphate 1.2%/benzoyl peroxide 3.75% gel. *J Drugs Dermatol* 2018;17:1107-12.
  50. Grandhi R, Alikhan A. Spironolactone for the treatment of acne: A 4-year retrospective study. *Dermatology* 2017;233:141-4.

**Source of Support:** Nil. **Conflicts of Interest:** None declared.