

Facial Nerve Branching Pattern in the Parotid Region: A Cadaveric Study

Salah Eldeen Dafalla

Department of Anatomy, Ibn Sina National College for Medical Studies, Jeddah, 22421, Kingdom of Saudi Arabia

Abstract

Introduction: The present study's objective was to examine the parotid region's facial nerve branching pattern. One of the 12 pairs of cranial nerves, the facial nerve (VII), travels through the stylomastoid foramen to the parotid area. It then passes through the parotid gland's posteromedial surface. The substance of the parotid gland has a complicated branching pattern and divides into five terminal branches. The platysma and face muscles are innervated by these branches. Based on the presence of anastomoses or communications between the terminal branches, its complicated branching pattern has been divided into many categories. **Materials and Methods:** Twenty-one cadaveric hemi faces were used as a sample, and the dissected specimen photos were photographed. The location of the facial nerve division, its relationship to the retromandibular vein, and the number of divisions was all documented in the dissected specimens. **Results and Discussion:** For head-and-neck surgeons, the facial nerve's branching pattern is crucial. The safe removal of the parotid gland without causing facial nerve damage is key to the success of the procedure. **Conclusion:** The success rate of parotid procedures will be impacted by understanding of potential anatomical variances. To minimize post-operative problems, medical staff must be aware of these variations.

Key words: Facial nerve, facial nerve branching, facial nerve divisions, parotid gland, parotid region

INTRODUCTION

The facial nerve, the seventh cranial nerve (number VI), enters the parenchyma of the parotid gland after passing through the stylomastoid foramen of the skull. The nerve divides into temporofacial and cervicofacial trunks near the parotid gland parenchyma just behind and superficial to the retromandibular vein. To create the parotid plexus or pes anserinus, these trunks further split. The parotid plexus, which supplies the muscles of the face and platysma, gives rise to the temporal, zygomatic, buccal, marginal mandibular, and cervical branches. There are six different types of branching patterns for the facial nerve in the parotid gland. Type I has no anastomosis between facial nerve branches; Type II has anastomosis between branches of the temporofacial division; Type III: The temporofacial and cervicofacial divisions have a single anastomosis; Type-IV: a combination of Types II and III; Type VI is a plexiform pattern in which a branch from the marginal mandibular unites with any branches of the temporofacial division. Type V: There are two anastomoses from the cervicofacial trunk that joins with

branches of the temporofacial division.^[1] The five different types of facial nerve branching patterns were also separated by Katz and Catalano: Type I: A conventional branching pattern; Type II: A zygomatic branch displayed a loop; Type III: A buccal branch had a loop; Type IV: A complex pattern with multiple interconnections; and Type V: Two trunks are present, one being major and the other is minor.^[2] The facial nerve and its branches split the parotid gland into superficial and deep lobes even though it does not have an anatomical plane as such.^[3,4]

The facial nerve's intra parotid branching pattern has been examined in several research. Even the ramification of the facial nerve's terminal branches was the subject of certain research. Studies have investigated visible landmarks that can be utilized to locate the facial nerve trunk. There is no research on the facial nerve branching in the parotid area,

Address for correspondence:

Dr. Salah Eldeen Dafalla, Department of Anatomy, Ibn Sina National College for Medical Studies, Jeddah, Kingdom of Saudi Arabia.
E-mail: shakeelqubal@gmail.com

Received: 12-06-2023

Revised: 19-09-2023

Accepted: 30-09-2023

though. Therefore, the objective of the current investigation was to investigate facial nerve ramification in the parotid region. The facial nerve's extratemporal journey is quite complicated because of how it interacts with other significant structures.^[5]

MATERIALS AND METHODS

The department of anatomy, Ibn Sina National College for Medical Studies, where the present study was carried out. From the cadavers available in the department 11 fresh adult formalin-fixed cadavers were chosen for the study. Cadavers with trauma, injury, and scar in the parotid region were excluded from the study. Bilateral parotid region dissection was done in ten cadavers and one cadaver was dissected unilaterally in semi lateral position ($n = 21$ hemi faces).^[6,7] Skin, subcutaneous tissue, and superficial fascia of the face have been reflected and the parotid gland was exposed. At the parotid gland's anterior border, the terminal branches of the facial nerve were located. Later, the gland was removed by the dissector using a piecemeal technique to protect the facial nerve's divisions and nerve branches.^[8] These divisions were traced proximal to their trunk. Following the dissection, the area was photographed. In relation to the parotid gland, the retromandibular vein, and the number of divisions in the facial nerve trunk, we have noted the location of the facial nerve division.

RESULTS AND DISCUSSION

Facial nerve division site

In the sample of 21 hemi faces from 11 cadavers, facial nerve in 16 hemi faces was divided before entering the parotid gland Figures 1 and 2 (76.1%). Five hemi faces, facial nerve was divided in the parotid gland Figures 1 and 3 (23.8%). Post-parotid division was not observed in any of the cadavers. However, one cadaver showed right-side pre-parotid division of facial nerve while on the left side, it was divided within the parotid gland.

Retromandibular vein to facial nerve relation

In 17 hemi faces, the retromandibular vein was medial to the facial nerve Figures 4 and 5. One hemi face, the vein was between divisions of facial nerve on the left side. In three hemi faces, the retromandibular vein was lateral to the nerve Figures 4 and 6.

Number of divisions of facial nerve

In all the hemi faces, the facial nerves were divided into upper and lower trunks only (two divisions) Figure 7.

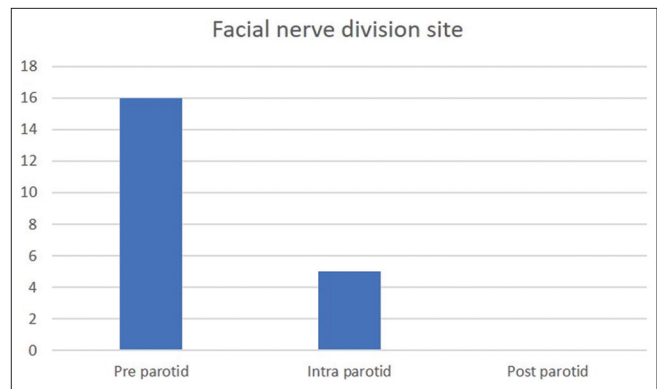


Figure 1: Bar chart shows the site of facial nerve division in relation to parotid gland

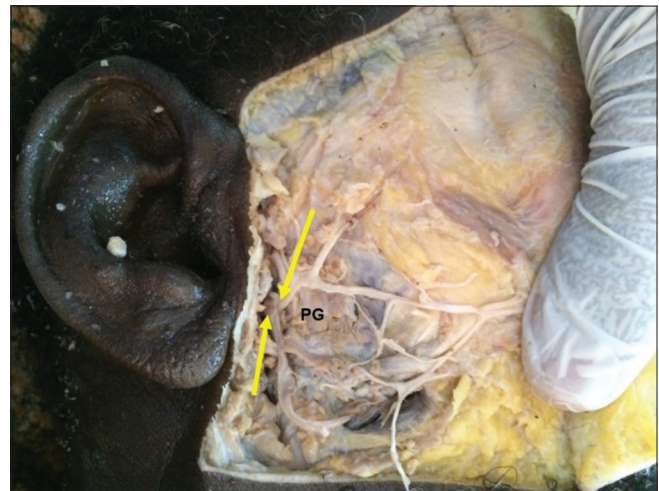

Figure 2: Lateral view of right hemi face, note yellow arrow denotes facial nerve trunks. PG: parotid gland



Figure 3: Lateral view of right hemi face, note yellow arrow denotes facial nerve trunks. PG: Parotid gland

Facial nerve branching pattern in parotid region is imperative to the surgeons. The branching pattern of facial nerve is not necessary to be the same on either side of the face. As in our situation, one cadaver displayed pre-parotid division on the right side whereas intraparotid division was present on the

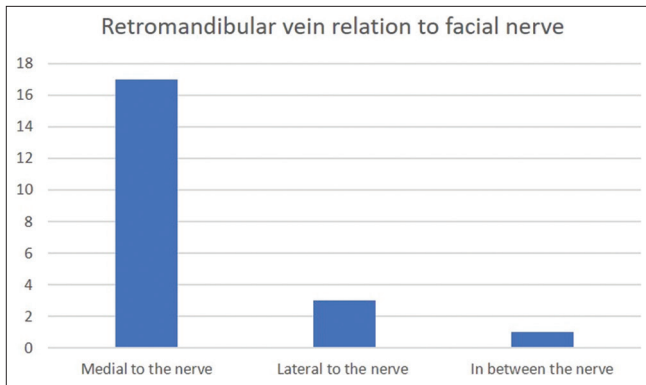


Figure 4: Bar chart shows the relation retromandibular vein to the nerve

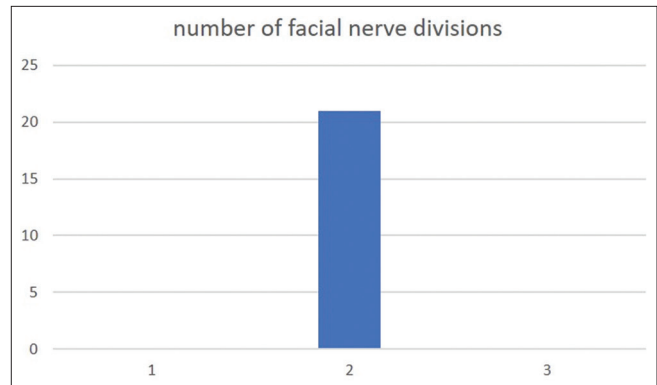


Figure 7: Bar chart shows the number of divisions of facial nerves

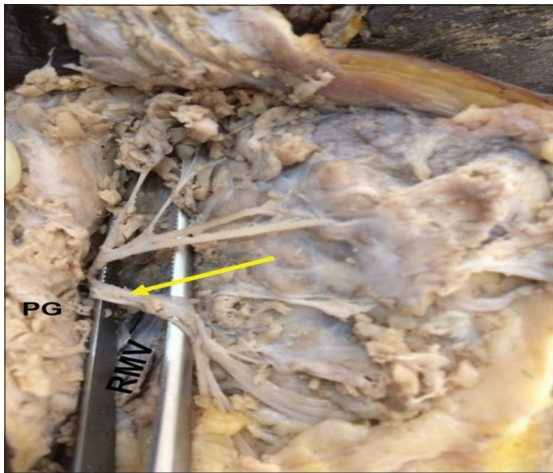


Figure 5: Lateral view of face, note yellow arrow denotes facial nerve trunk. PG: Parotid gland, RMV: Retromandibular vein

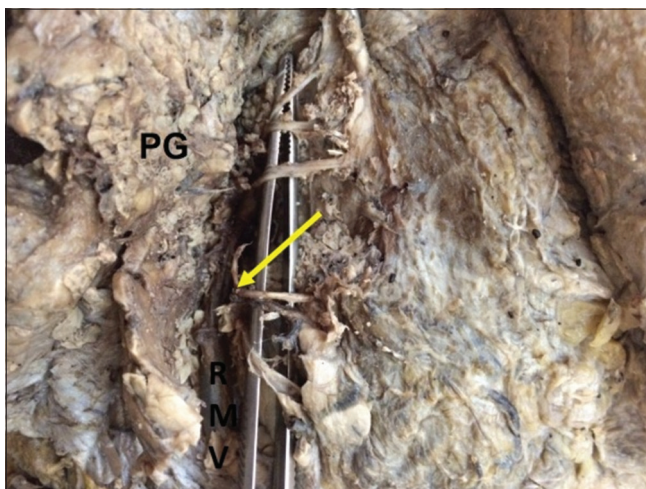


Figure 6: Lateral view of right hemi face, note yellow arrow denotes facial nerve trunk. PG: Parotid gland, RMV: Retromandibular vein

left. Davis classification of Type I is clinically important, if there is an injury to any one branch, it will lead to paralysis of facial muscles as there is no anastomosis among the branches. However, recovery from facial muscle paralysis

is faster with the complex branching pattern.^[9] Advantage of having anastomosis or inter connections is that, injury to any of the branch will not cause complete functional loss of the muscle.^[10]

Parotid gland tumors require partial or total parotidectomy, this surgery poses great risk because of gland and facial nerve relation.^[11] Pediatric facial paralysis often arises by parotid surgery.^[12] Therefore, identification of facial nerve and its branches is important before the excision of tumor.^[13] Surgeons should bear in mind the possible anatomical variations of facial nerve to minimize the risk of injury to facial nerve. Mandibular condylar fracture reduction, decompression of stylomastoid foramen and temporomandibular joint ankylosis require surgical approach in the preauricular region.^[14,15] Risk of facial nerve injury is 42.9% in such pre-auricular surgical approach.^[16] In the present study, few facial nerves are divided even before they enter the parotid gland. This type of facial nerve division is highly vulnerable for injury during mandibular condylar fracture reduction procedure. Because of limited space between mastoid process and parotid gland performing procedures in this area would be extremely difficult presence of pre-parotid branching adds even more difficulty to it.^[17]

Facial nerve trunk may divide into its upper and lower divisions either before or after entering the parotid gland. In the present study, also few facial nerve trunks divided before entering the parotid gland. The bifurcation of facial nerve and its location is highly variable among individuals and same individual between the two sides of the face. In the present study, all the facial nerve trunks had bifurcation. We could not observe any non-bifurcated or trifurcated facial nerve trunks.^[18] Even though several bony landmarks such as the styloid, mastoid process, tympanomastoid suture, external auditory canal, and soft-tissue anatomical landmarks such as the posterior belly of the digastric muscle and the tragus^[19] are available to locate the facial nerve trunk and its branches, it is extremely difficult to identify the exact location of the facial nerve trunk because of the high variations. Post-operative facial paralysis is on the rise because of the high variability of facial nerve branching.^[20] Awareness of the facial nerve branching pattern reduces post-operative morbidity.

CONCLUSION

The facial nerve branching pattern is highly variable. In the present study, pre-parotid branching is very common in the study sample. Facial nerve division on both sides is different, even in the same individual. Medical personnel must be aware of these variations to reduce post-operative complications.

ACKNOWLEDGMENTS

The author would like to extend their gratitude and acknowledgment ISNC Jeddah, KSA.

REFERENCES

- Davis RA, Anson BJ, Budinger JM, Kurth LR. Surgical anatomy of the facial nerve and parotid gland based upon a study of 350 cervico-facial halves. *Surg Gynecol Obstet.* 1956;102:385-412.
- Katz AD, Catalano P. The clinical significance of the various anastomotic branches of the facial nerve. Report of 100 patients. *Arch Otolaryngol Head Neck Surg* 1987;113:959-62.
- Joseph ST, Sharankumar S, Sandya CJ, Sivakumar V, Sherry P, Krishnakumar T, *et al.* Easy and safe method for facial nerve identification in parotid surgery. *J Neurol Surg B Skull Base* 2015;76:426-31.
- Hwang K. Surgical anatomy of the facial nerve relating to facial rejuvenation surgery. *J Craniofac Surg* 2014;25:1476-81.
- Bernstein L, Nelson RH. Surgical anatomy of the extraparotid distribution of the facial nerve. *Arch Otolaryngol* 1984;110:177-83.
- Kotharkar AV. Assessment of Facial Nerve in Retromandibular Approach for Condylar and Sub Condylar Region: A Cadaveric Study (Doctoral Dissertation) Publishing; 2017. p. 30282475.
- Audolfsson T, Rodríguez-Lorenzo A, Wong C, Cheng A, Kildal M, Nowinski D, *et al.* Nerve transfers for facial transplantation: A cadaveric study for motor and sensory restoration. *Plast Reconstr Surg* 2013;131:1231-40.
- Nadershah M, Salama A. Removal of parotid, submandibular, and sublingual glands. *Oral Maxillofac Surg Clin North Am* 2012;24:295-305, x.
- Weerapant E, Bunaprasert T, Chokrungravanont P, Chentanez V. Anatomy of the facial nerve branching patterns, the marginal mandibular branch and its extraparotid ramification in relation to the lateral palpebral line. *Asian Biomed* 2010;4:603-8.
- Park IY, Lee ME. A morphological study of the parotid gland and the peripheral branches of the facial nerve in Koreans. *Yonsei Med J* 1977;18:45-51.
- Gasser RF. The early development of the parotid gland around the facial nerve and its branches in man. *Anat Rec* 1970;167:63-77.
- Farrior JB, Santini H. Facial nerve identification in children. *Otolaryngol Head Neck Surg* 1985;93:173-6.
- Greyling LM, Glanvill R, Boon JM, Schabert D, Meiring JH, Pretorius JP, *et al.* Bony landmarks as an aid for intraoperative facial nerve identification. *Clin Anat* 2007;20:739-44.
- Laurentjoye M, Veyret A, Ella B, Uzel AP, Majoufre-Lefebvre C, Caix P, *et al.* Surgical anatomy of the preauricular anteroparotid approach for mandibular condyle surgery. *Surg Radiol Anat* 2014;36:883-8.
- Narayanan V, Ramadorai A, Ravi P, Nirvikalpa N. Transmasseteric anterior parotid approach for condylar fractures: Experience of 129 cases. *Br J Oral Maxillofac Surg* 2012;50:420-4.
- Pereira MD, Marques A, Ishizuka M, Keira SM, Brenda E, Wolosker AB. Surgical treatment of the fractured and dislocated condylar process of the mandible. *J Craniomaxillofac Surg* 1995;23:369-76.
- Yokoyama J, Ooba S, Fujimaki M, Anzai T, Kojima M, Ikeda K. Impact of removing mastoid process for advanced parotid cancer on facial nerve identification, preservation and reconstruction. *Head Face Med* 2014;10:6.
- Rana S, Akhtar UB, Atif S, Javaid Z. Terminal branching pattern of facial nerve seen in adult cadavers: An anatomical study. *Ann Punjab Med Coll* 2017;11:311-5.
- Babuci A. Types of extracranial branching of the facial nerve. *Moldovan Med J* 2019;62:41-4.
- Stankevicius D, Suchomlinov A. Variations in facial nerve branches and anatomical landmarks for its trunk identification: A pilot cadaveric study in the Lithuanian population. *Cureus* 2019;11:e6100.

Source of Support: Nil. **Conflicts of Interest:** None declared.